



DIAGNOSTIC FEATURES OF NEUROSONOGRAPHY IN INTRAUTERINE INFECTION IN NEWBORNS

Usmanova Munira Fayzullayevna

*Assistant of the Department of №1 Pediatrics and neonatology
Samarkand State Medical University*

Tolibjonova Nozanin Xusenovna

*Student of the 622th group of the Faculty of Pediatric
Samarkand State Medical University*

Annotation. *In the article are given data 60 newborns with gestation period from 28 to 41 weeks with hypoxic lesion of the CNS of the early period. At all stages of the study and observation of newborns conducted a collection of gynecological, obstetric anamnesis, studied the specifics of the course of pregnancy and childbirth. The early neonatal period was assessed by taking into account the data of gestational age, mass and length of the body at birth, the circumference of the head and stem cells, physiological destruction of the mass of the body, analyzed the state of recurrence of childbirth. The dynamics of the neuropsychological status of the examined children was assessed.*

Keywords: *hypoxia, central nervous system, neonatal period, gestation period.*

Introduction. Intrauterine infections (IUIs) are characterized by polyetiology, the absence of specific signs and a wide variety of clinical manifestations, which complicates their antenatal diagnosis and, as a consequence, preventive measures and treatment of a realized infection [8,9,12]. Neurosonography (NSG) is currently the primary screening method of research, due to its ease of implementation and relative availability. Neurosonography is a



method of two-dimensional ultrasound examination of the anatomical structures of the brain, which uses the property of sound to be reflected from the boundaries of tissue structures [3,4,14]. Acoustic windows: large and small fontanelles, defects in the bones of the skull, enlarged sutures, foramen magnum in newborns. The method is non-invasive, does not require preliminary preparation and allows you to trace the dynamics of the pathological process in real time. The image is presented on the monitor screen in the form of signals of hyper- and hypoechoic density [10,15].

The method is used for prenatal and postnatal diagnostics of cerebral malformations; hypoxic-ischemic, hemorrhagic, traumatic and inflammatory brain injuries and their consequences; tumors, ventriculomegaly. A sign of cerebral ischemia is the presence of diffuse hyperechoic foci, more often in the periventricular region, expansion of the interhemispheric groove, subarachnoid spaces, symmetrical expansion of the ventricular system [1,2,7,10]. Intraventricular hemorrhages (IVH) and parenchymal-hyperechoic formations with clear contours, located intraventricularly, subcortically or cortically. Has great diagnostic value in assessing the severity of GIE in newborns [5,6,11,13].

Objective: Determination of the nature of neurosonographic data in hypoxic-ischemic encephalopathy in newborns with intrauterine infection.

Materials and methods: A study was conducted in 24 full-term newborns who had intrauterine infection and with signs of DIE according to anamnestic, clinical and paraclinical data. All children underwent neurosonographic studies on the 3rd, 5-7, 14-16 days of life.

Research results: The overall frequency of neurosonographic changes in newborns with HIE was 55.6%. The predominant symptom in the early neonatal period was a local increase in echogenicity, the frequency of which significantly decreased by the end of the first week of life. The neurosonographic picture had a



certain staging in the dynamics of the neonatal period, which made it possible to identify 2 NSH variants of its course in newborns with moderate HIE.

The first option: a local increase in echogenicity - expansion of the interhemispheric groove. The latter could indicate the presence of atrophic changes in the brain tissue. The presence of this variant could be determined in 24 newborns who had changes in the NSH picture.

The second option: a local increase in echogenicity - an increase in the echogenicity of the choroidal plexuses - a moderate increase in the lateral ventricles, subarachnoid space. This variant was more common in 24 children with neurosonographic changes (Fig1.).

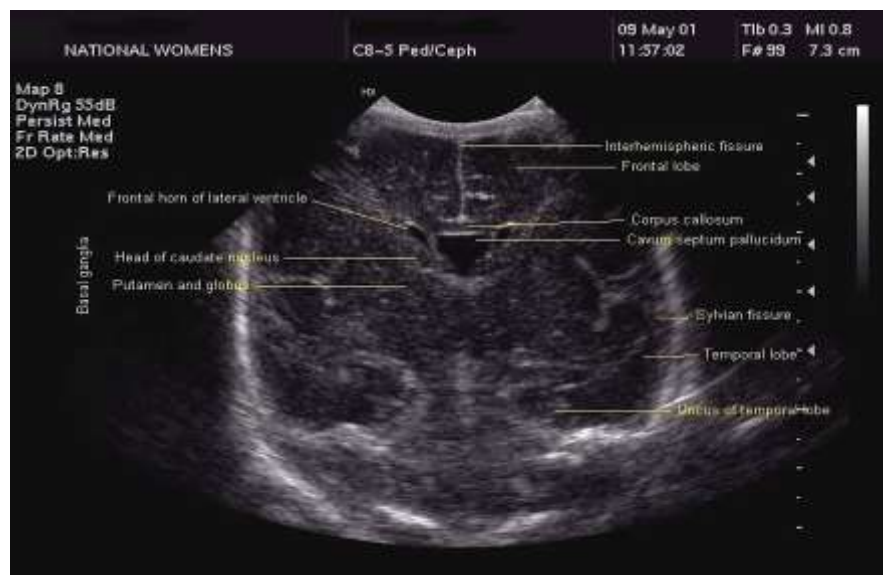


Figure 1. Ultrasound of the brain.

The advantages of ultrasound methods in examining the brain in children of the first year of life are obvious. Non-invasiveness, absence of radiation exposure, and the possibility of dynamic research make echography one of the main diagnostic methods in perinatal neurology. No special training or anesthesia is required. Modern ultrasound methods make it possible to assess not only the structure of the brain, but also the state of cerebral blood flow. The severity of the underlying disease is not a contraindication for neurosonography (Table 1).

Table 1.



Characteristics of neurosonography data in newborns on the 5-7th day of life

Indicators	1st group	2nd group	Group 3
Periventricular edema	18 (90%)	16 (80%)	13 (65%)
IVH of 1 degree	5 (25%)	3 (15%)	2 (10%)
IVH of the 2nd degree	3 (15%)	2 (10%)	15%)
Dilation of the lateral ventricles	5 (25%)	4 (20%)	3 (15%)

Periventricular cerebral edema, which occurs as a result of intrauterine or intrapartum hypoxia, was found much more often among others in all examined children. In all comparison groups, both full-term and premature newborns, periventricular edema was observed with approximately the same frequency. There was no significant difference between the groups.

Dilation of the lateral ventricles, as a manifestation of hypertensive syndrome, was detected both in full-term newborns - 15%, and in premature newborns of groups 1 and 2 (25% and 20%, respectively)

There were no children with signs of periventricular leukomalacia among the studied groups at the age of 5 - 7 days. In premature infants of groups 1 and 2, hemorrhagic changes were more often recorded on NSH (IVH of I and II degrees) compared with full-term infants.

Thus, in the early neonatal period in newborns with DIE, according to the data of ultrasound examination of the brain, dilatation of the lateral ventricles and the phenomenon of periventricular cerebral edema are quite often revealed, which indicates a deep degree of CNS damage in newborns of this group.

Hypoxic-hemorrhagic lesions of the central nervous system were significantly more frequent in premature infants. At the age of one month in newborns with HIE, various changes in the structure of the brain persisted. According to the NSG, there was a significant decrease in the incidence of



periventricular edema over time, but it still persisted in 40% of children in group 1 of full-term infants, in 30% of children born with a gestational age of 32-37 weeks, and in 20% of full-term infants.

This indicator of hypoxic-ischemic damage to the central nervous system decreased by almost 2-3 times ($p < 0.01$) compared with the early neonatal period in all observation groups. Subependymal cysts, according to the ultrasound examination of the brain, in most cases as a consequence of the transferred intraventricular hemorrhage, were recorded only in premature infants 5% and 10%, respectively, in groups 1 and 2.

Dilation of the lateral ventricles in newborns at 1 month was noted less frequently in all observation groups than in the early neonatal period (15%, 10%, and 5%, respectively, in groups 1, 2 and 3). It was also noted that the number of premature newborns in the neonatal period who did not have pathological changes on neurosonography was significantly ($p < 0.05$) less than in the comparison group, where normal neurosonograms were detected in almost half of the examined newborns, 10% and 15% in groups of premature babies, versus 40% in the group of full-term newborns. Hypoxic-hemorrhagic lesions of the central nervous system (IVH grade I) at the end of the neonatal period were diagnosed in children in 15% and 10% of groups 1 and 2, respectively. 1 full-term newborn from the comparison group also had grade I IVH.

The results obtained indicate that in premature infants with DIE, gross structural changes in the brain according to ultrasound (PVO, IVH) persist longer.

At the age of 3 months, during neurosonography, it was noted that in the group of full-term newborns, most children did not have pathological changes (65%), while in the groups of premature babies, their number was much less than 25% and 35%, respectively ($P < 0.05$). the incidence of lateral ventricular dilatations also decreased compared to 1 month of age, but had no confidence limits. Subependymal cysts persisted in 5% of group 1 premature infants and 10%



of group 2 premature infants.

Conclusions: Thus, deviations from the norm in the neurosonographic picture are observed in 55% of newborns with moderate hypoxic-ischemic encephalopathy. The main variants of neurosonographic changes were: a local increase in echogenicity - expansion of the interhemispheric sulcus and a local increase in echogenicity - an increase in echogenicity of the choroidal plexus - a moderate increase in the lateral ventricles, subarachnoid space.

BIBLIOGRAPHY

1. Aleksandrova V.A. Perinatal lesions of the central nervous system and their consequences in the practice of a pediatrician: a textbook for doctors / V.A. Alexandrova, E.A. Bratova .- SPb., 2018 .- 70 p.
2. Amasyants, R.A. Clinic of intellectual disorders: Textbook / R.A. Amasyants, E.A. Amasyants. - Moscow: Pedagogical Society of Russia, 2016. - 320 p.
3. Afonin, A.A. Dynamics of indicators of cerebral hemodynamics and endothelium of dependent factors of its regulation in children with perinatal CNS damage in the first year. Afonin, V.V. Strogulin, I. G. Loginova, N.A. and others // Pediatrics.-2011.-Т. 90.-№ 1.-p.30-33.
4. Bakanov, M.I. Clinical and diagnostic value of enolase and basal myelin in newborns with perinatal hypoxic lesions of the central nervous system / M.I. Bakanov, V.V. Altyrtsev, O.V. Goncharova et al. // Russian Medical Journal.- 2013.-No.4.-P. 19-23.
5. Bakanov, M.I. New biochemical criteria for the diagnosis and prognosis of perinatal lesions of the central nervous system in newborn children / M.I. Bakanov, V.V. Alatyrtseva, V.N. Podkopaev // Scientific Center of Children's Health of the Russian AMN-Moscow.-2011.-235p.



6. Baranov, A.A. The state of health of children in the Russian Federation / A.A. Baranov // Pediatrics. 2012.-Т. 91.-No. 3.- S. 9-14.
7. Vasilenko L.V., Zryachkin N.I., Vasilenko T.L. 2008; 3: 73-76.
8. Sirojiddinova X.N., Nabieva Sh.M., Ortikboyeva N.T. Intrauterine infection as a developmental factor perinatal pathology // Central asian journal of medical and natural sciences Volume: 02 Issue: 01 | Jan-Feb 2021 ISSN: 2660-4159. On page 107-111.
9. Sirojiddinova X.N., Usmanova M.F., Ortikboyeva N.T., Tuxtayeva M.M. Immunological dynamics of recurrent respiratory infections in frequently sick children on the background of immunocorrective therapy // IJIEMR Transactions, online available on 11 April 2021.Vol 10. On page 131-134.
10. Sirojiddinova X.N., Ikromova Z.X., Nabiyeva Sh.M., Ortikbayeva N.T., Abdullayeva G.D. Metabolic Changes Following Post-Hypoxic Complications in Newborns // International Journal of Current Research and Review DOI: <http://dx.doi.org/10.31782/IJCRR.2020.122229>. Scopus. On page [173-177](#).
11. Sirojiddinova X.N., Ortikboyeva N.T., Aminova N.A., Akmaljanova A. A. Peculiarities of neurosonography in hypoxic-ischemic encephalopathy in newborns with intrauterine infection // Eurasian journal of academic research. Volume 1 Issue 9, December 2021 ISSN 2181-2020. On page 261-265.
12. Tukhtaeva M.M., Usmanova M.F., Omonova G.Z., Ochilova B.S. Psychomotor changes in hypoxic lesions of the central nervous system in newborns // Eurasian journal of academic research. Volume 1 Issue 9, December 2021 ISSN 2181-2020. On page 271-275.
13. Tukhtaeva M.M., Abduxalik-Zade G.A., Burxonova D.B., Mirkomilova G.M. Clinic - anamnestic characteristic of hypoxic-ischemic encephalopathy in newborns // Eurasian journal of academic research. Volume 1 Issue 9, December 2021 ISSN 2181-2020. On page 261-265.



14. Usmanova M.F. Sirojiddinova X.N. Actual problems of diagnosis of hemolytic disease in newborns // European International Journal of Multidisciplinary Research and Management Studies. 30.04.2022. Vol. 2 (4) on Page 282-289.

15. Usmanova M.F. Sirojiddinova X.N. Modern approaches to the detection of hemolytic disease in newborns // European International Journal of Multidisciplinary Research and Management Studies. 30.04.2022. Vol. 2 (4) on Page 274-281.